



In Vivo Phenotyping of Tumor Metabolism in a Canine Cancer Patient with Simultaneous (18)F-FDG-PET and Hyperpolarized (13)C-Pyruvate Magnetic Resonance Spectroscopic Imaging (hyperPET): Mismatch Demonstrates that FDG may not Always Reflect the Warburg Effect

Gutte, Henrik; Hansen, Adam E; Larsen, Majbrit M E; Rahbek, Sofie; Johannesen, Helle H; Ardenkjær-Larsen, Jan Henrik; Kristensen, Annemarie T; Højgaard, Liselotte; Kjær, Andreas

Published in:
Diagnostics

Link to article, DOI:
[10.3390/diagnostics5030287](https://doi.org/10.3390/diagnostics5030287)

Publication date:
2015

Document Version
Publisher's PDF, also known as Version of record

[Link back to DTU Orbit](#)

Citation (APA):

Gutte, H., Hansen, A. E., Larsen, M. M. E., Rahbek, S., Johannesen, H. H., Ardenkjær-Larsen, J. H., ... Kjær, A. (2015). In Vivo Phenotyping of Tumor Metabolism in a Canine Cancer Patient with Simultaneous (18)F-FDG-PET and Hyperpolarized (13)C-Pyruvate Magnetic Resonance Spectroscopic Imaging (hyperPET): Mismatch Demonstrates that FDG may not Always Reflect the Warburg Effect. *Diagnostics*, 5(3), 287–289. <https://doi.org/10.3390/diagnostics5030287>

General rights

Copyright and moral rights for the publications made accessible in the public portal are retained by the authors and/or other copyright owners and it is a condition of accessing publications that users recognise and abide by the legal requirements associated with these rights.

- Users may download and print one copy of any publication from the public portal for the purpose of private study or research.
- You may not further distribute the material or use it for any profit-making activity or commercial gain
- You may freely distribute the URL identifying the publication in the public portal

If you believe that this document breaches copyright please contact us providing details, and we will remove access to the work immediately and investigate your claim.

Interesting Images

***In Vivo* Phenotyping of Tumor Metabolism in a Canine Cancer Patient with Simultaneous ¹⁸F-FDG-PET and Hyperpolarized ¹³C-Pyruvate Magnetic Resonance Spectroscopic Imaging (hyperPET): Mismatch Demonstrates that FDG may not Always Reflect the Warburg Effect**

Henrik Gutte ¹, Adam E. Hansen ¹, Majbrit M.E. Larsen ², Sofie Rahbek ¹,
Helle H. Johannesen ¹, Jan Ardenkjaer-Larsen ^{3,4}, Annemarie T. Kristensen ²,
Liselotte Højgaard ¹ and Andreas Kjaer ^{1,*}

¹ Department of Clinical Physiology, Nuclear Medicine & PET and Cluster for Molecular Imaging, Rigshospitalet, University of Copenhagen, Copenhagen 2100, Denmark;

E-Mails: gutte@sund.ku.dk (H.G.); adam.espe.hansen@regionh.dk (A.E.H.);
sofie89falko@gmail.com (S.R.); helle.hjorth.johannesen.01@regionh.dk (H.H.J.);
liselotte.hoejgaard@regionh.dk (L.H.)

² Department of Veterinary Clinical and Animal Sciences, Faculty of Health and Medical Sciences, University of Copenhagen, Frederiksberg C 2000, Denmark;

E-Mails: majbritt.larsen@sund.ku.dk (M.M.E.L.); atk@sund.ku.dk (A.T.K.)

³ Department of Electrical Engineering, Technical University of Denmark, Lyngby 2800, Denmark;

E-Mail: JanHenrik.ArdenkjaerLarsen@ge.com

⁴ GE Healthcare, Brøndby 2605, Denmark

* Author to whom correspondence should be addressed; E-Mail: akjaer@sund.ku.dk;

Tel.: +45-3545-4216; Fax: +45-3545-4015.

Academic Editor: Graham Jackson

Received: 13 May 2015 / Accepted: 19 June 2015 / Published: 26 June 2015

Abstract: In this communication the mismatch between simultaneous ¹⁸F-FDG-PET and a ¹³C-lactate imaging (hyperPET) in a biopsy verified squamous cell carcinoma in the right tonsil of a canine cancer patient is shown. The results demonstrate that ¹⁸F-FDG-PET may not always reflect the Warburg effect in all tumors.

Keywords: cancer; dynamic nuclear polarization; hyperpolarized; ^{13}C -pyruvate; MR; ^{18}F -FDG-PET; PET/MR; molecular imaging; hyperPET

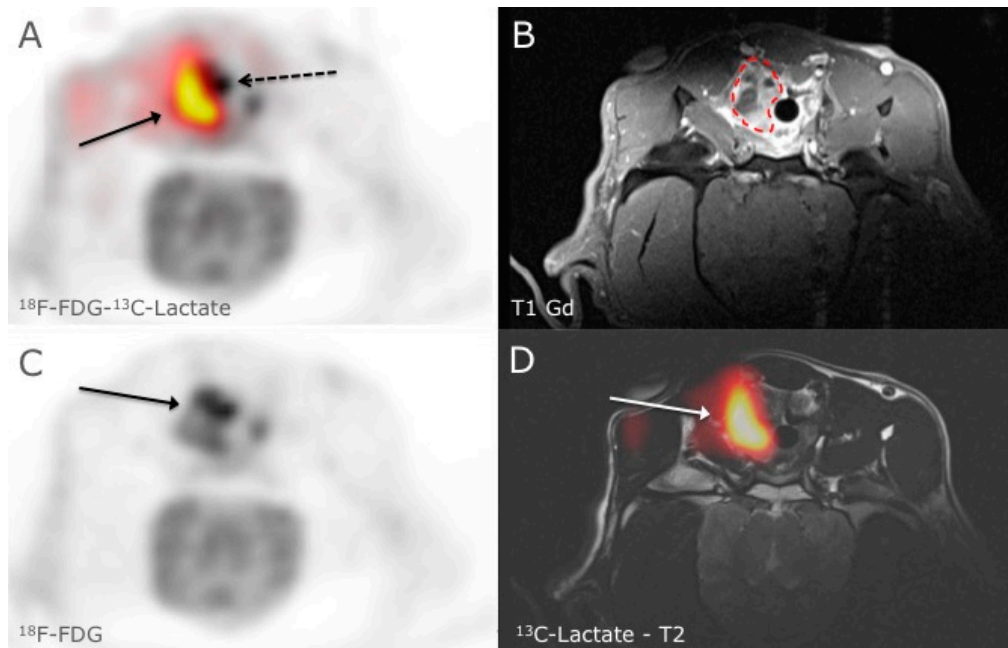


Figure 1. HyperPET is a new *in vivo* imaging modality that consists of combining a PET scan with magnetic resonance spectroscopic imaging (MRSI) of hyperpolarized ^{13}C -pyruvate made possible by integrated hybrid PET/MRI systems [1]. The metabolism of cancer cells is characterized by a shift to glycolysis with production of lactate even in the presence of sufficient oxygen, this phenomenon is also known as the Warburg effect [2–4]. With the introduction of hyperpolarized ^{13}C -pyruvate/ ^{13}C -lactate MRSI it is probably now possible to directly study the metabolism of lactate and Warburg effect in real time. This is opposed to imaging with ^{18}F -FDG PET scan alone, which demonstrates the Warburg effect only indirectly through increased glucose utilization and uptake. In Figure 1, ^{18}F -FDG-PET and ^{13}C -lactate MRSI in a spontaneous canine tumor is shown. A clear mismatch between ^{18}F -FDG uptake and ^{13}C -lactate production is seen. In an axial slice of the neck in a canine cancer patient with a biopsy verified squamous cell carcinoma in the right tonsil, we noticed in panel A clear discrepancy between the ^{18}F -FDG-PET (^{18}F -FDG activity is shown in grey scale and the dashed arrow points at the margin of tumor) and the ^{13}C -lactate production (red to yellow color corresponds to the ^{13}C -Lactate production and the arrow points to the margin of tumor) in a large heterogeneous tumor. ^{18}F -FDG uptake in the tumor was variable in the tumor (panel C) and corresponded to the anatomical MR images in that high ^{18}F -FDG levels paralleled the uptake of Gadolinium in the T1 sequence (panel B, dashed line outlines the contour of the tumor). However ^{13}C -lactate did not correspond to the ^{18}F -FDG uptake, especially in the more profound region of the tumor where we demonstrated a large production of ^{13}C -lactate indicating higher degree of glycolysis (panel D). The Ethics and Administrative Committee, Department of Veterinary

Clinical and Animal Sciences, Faculty of Health and Medical Sciences, University of Copenhagen approved the study. Whereas ^{18}F -FDG-PET has generally been accepted as an indicator of the Warburg effect the hyperPET imaging of a canine tumor demonstrates that this may not always be the case. Accordingly, the new technique of hyperPET that we recently introduced can expose such diversity in metabolism. We suggest that hyperPET may become a valuable tool for better phenotyping of tumors to be used for prognostication, treatment planning and response monitoring.

Acknowledgments

The financial support from the John and Birthe Meyer Foundation and the Capital Region of Denmark is gratefully acknowledged. Karin Stahr, Marianne Federspiel, Jakup Poulsen and Betina Senius Pedersen are acknowledged for invaluable technical assistance.

Author Contributions

Henrik Gutte wrote the initial draft of the manuscript, with all authors making substantial contributions to evaluation of data and critically reviewing its content. All authors have approved the final version of the manuscript prior to its submission.

Conflicts of Interest

The authors declare no conflict of interest.

References

1. Gutte, H.; Hansen, A.E.; Henriksen, S.T.; Johannesen, H.H.; Ardenkjaer-Larsen, J.; Vignaud, A.; Hansen, A.E.; Børresen, B.; Klausen, T.L.; Wittekind, A.M.N.; *et al.* Simultaneous hyperpolarized ^{13}C -pyruvate MRI and ^{18}F -FDG-PET in cancer (hyperPET): Feasibility of a new imaging concept using a clinical PET/MRI scanner. *Am. J. Nuclear Med. Mol. Imaging* **2015**, *5*, 38–45.
2. Johnbeck, C.B.; Jensen, M.M.; Nielsen, C.H.; Hag, A.M.F.; Knigge, U.; Kjær, A. ^{18}F -FDG and ^{18}F -FLT-PET Imaging for Monitoring Everolimus Effect on Tumor-Growth in Neuroendocrine Tumors: Studies in Human Tumor Xenografts in Mice. *PLoS ONE* **2014**, *9*, e91387.
3. Vander Heiden, M.G.; Cantley, L.C.; Thompson, C.B. Understanding the Warburg Effect: The Metabolic Requirements of Cell Proliferation. *Science* **2009**, *324*, 1029–1033.
4. Jensen, M.M.; Erichsen, K.D.; Johnbeck, C.B.; Björkling, F.; Madsen, J.; Jensen, P.B.; Sehested, M.; Højgaard, L.; Kjær, A. ^{18}F FDG and ^{18}F FLT positron emission tomography imaging following treatment with belinostat in human ovary cancer xenografts in mice. *BMC Cancer* **2013**, *13*, 168.